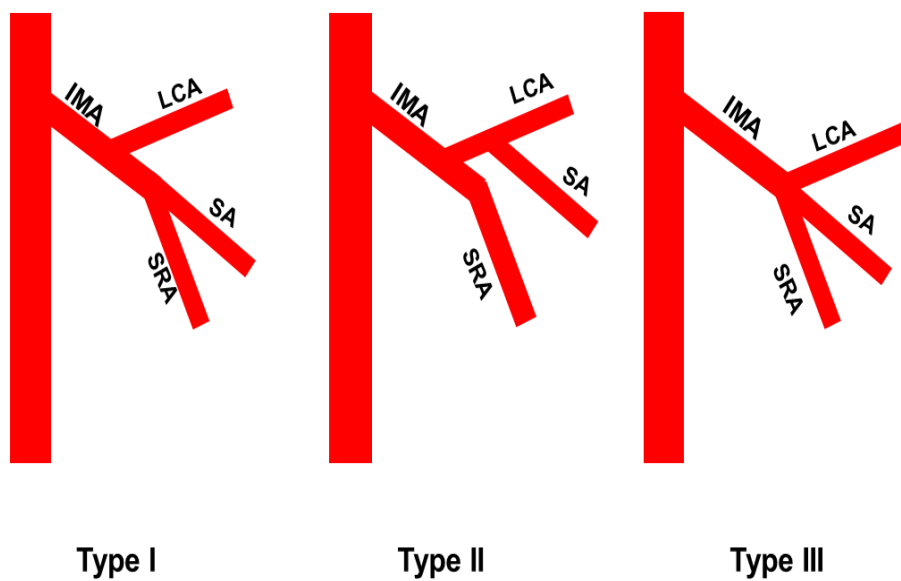


Application Of a Three-Dimensional Printed Inferior Mesenteric Artery Model in Laparoscopic Radical Resection with Preservation of Left Colic Artery for Rectal Cancer

Supplementary Description

Zongxian Zhao^{1}, Zongju Hu¹, Qinlingfei Liu², Xinyu Su¹, Shu Zhu¹*



Supplementary Figure 1: The three branching types of the IMA